

An approach to mapping between the classification of diseases ICD-10 and the Ontology of Ultrasound Images of hepato-pancreato-biliary zone organs

Abstract — This paper presents a method of context-driven annotation in images of the DICOM standard [1] and its application for ultrasound images. Here is described our attempt to create a mapping between the Classification of Diseases ICD-10 [2], and the Ontology of Ultrasound Images (OUI) of hepato-pancreato-biliary zone organs [3].

Index Terms — hepato-pancreato-biliary zone, DICOM images, ontology mapping, gallbladder pathology, ultrasound images.

Natalia BRUC

Institutul de Matematică și Informatică AȘM
natabruc@math.md

I. METHOD OF CONTEXT-DRIVEN ANNOTATION IN DICOM IMAGES

One of the standards for the creation, storage, transmission and visualization of medical images is a DICOM standard (Digital Imaging and Communications in Medicine).

DICOM file contains information about the patient, the physician, the date of investigation, about the medical institution in which the investigation was made, and so on. However, this standard does not provide storage of data about the anatomy of the investigated organ and about relevant pathologies, therefore, does not provide possibility for searching images stored in the DICOM format by these criteria.

The question that has to be answered is: How to get the annotations and how to help physicians to annotate the received images, without expending any extra efforts.

In [4] it is presented a method of solving this problem for the radiological images.

In this approach, semantic annotations are included directly in the headers of DICOM images, and do not require any additional storage mechanisms. The described method allows: to annotate images by semantic concepts of anatomy ontology (FMA [5], RadLex [6]) and the diseases ontology (ICD), to save annotations in the headers of DICOM images and request annotations using semantic concepts.

The authors of [4] integrated semantics of anatomy and diseases (Radlex, FMA and ICD9), notably there was created a mapping between the anatomy and disease ontologies. On the basis of the ICD9 there was created an OWL ontology, which reflects the hierarchical structure of the original classification.

Thanks to this technique, physicians have the opportunity to annotate the obtained images using the

ontology developed by the authors of [4], and subsequently to retrieve images using these annotations.

Our goal is to apply the proposed approach for ultrasound images.

II. APPLICATION OF THE METHOD OF CONTEXT-DRIVEN ANNOTATION IN DICOM IMAGES FOR THE ULTRASOUND IMAGES

Ultrasound investigation (USG) or sonography is currently the leader among the diagnostic methods. Ultrasound investigation has a number of undeniable advantages in comparison with other methods:

- it is the most widespread and effective method;
- the equipment cost for ultrasound investigation is much lower than for other investigation methods (magnetic resonance imaging, computerized tomography, digital radiography, and so on);
- it is noninvasive method of investigation, has a high diagnostic accuracy and stands out among the other methods due to its informativeness, quickness, reliability and painlessness of investigation.

In the Institute of Mathematics and Computer Sciences of Academy of Sciences of the Republic of Moldova there was developed a decision support system in the domain of ultrasound diagnostics of hepato-pancreato-biliary organs SonaRes [7]. The knowledge base of the SonaRes system was created during long-term cooperation of physicians-experts with computer science researchers and represents formal representation of experience and knowledge of physicians in the domain [8]. In fact, this knowledge base is an ontology [9], but for our goals, we had to present it in one of the standard formats.

We have constructed our ontology using the editor of ontologies Protégé [10]. In this case, we have not moved the whole structure and data, but in the course of

development the modifications and corrections concerning the structure of the ontology were made.

Solution of the problem of building of the ontology of ultrasound images (UI) is based on the fact that all UI of patients' organs have verbal descriptions. These descriptions are made with the help of medical terms - concepts and characteristics, among which there are the relations and dependencies. Thus, the problem of building of the ontology of UI turns to the task of building an ontology of UI descriptions (UID), which are associated with the appropriate UI (Fig. 1).

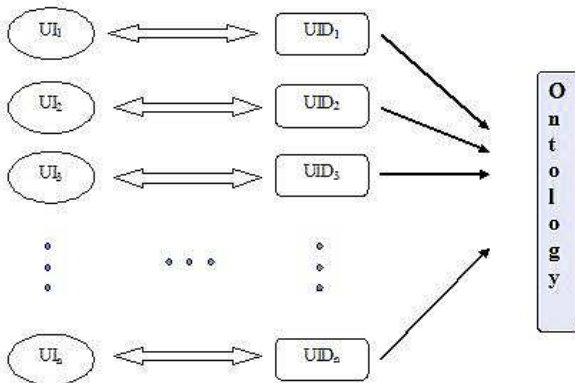


Fig.1. Correspondence between ultrasound images and their descriptions in building the UI ontology [11].

Following this approach [3] there was developed the ontology of gallbladder pathologies, which made it possible to establish its basic structure and principles of the determination of classes, subclasses, slots, and so on. This technology has already been applied to the other abdominal zone organs - liver and pancreas. Fig. 2 shows the structure of ontology of ultrasound images (OUI) of the hepato-pancreato-biliary zone organs.

The OUI consists of 5 main classes: *Organ*, *Pathology*, *Patient*, *Image* and *Complex_characteristics*. These classes are related to each other and located on the upper level of the ontology. The ontology has 4 levels of nesting.

Class *Organ* describes different organs (for now only the abdominal area) and is related with class *Pathology* to reflect, with what pathology the certain description of organ is related; with class *Patient* to display, what patient from the given database has this pathology; and with class *Complex_characteristics* to reflect, what characteristics the given organ has.

Class *Image* is a storage of all images of concrete patients and is related with the class *Patient* to reflect the relation: to which patient does the given image belong.

Class *Pathology* is the list of all pathologies structured by organs and different areas.

Class *Patient* is a storage of all patients and it is related with class *Pathology* to reflect, what pathologies the given patient has and with class *Image* to reflect, what images belong to the given patient.

Class *Complex_characteristics* describes the characteristics of the organ: main and additional. It is related with class *Pathology*, to reflect, to which pathology the given characteristic corresponds.

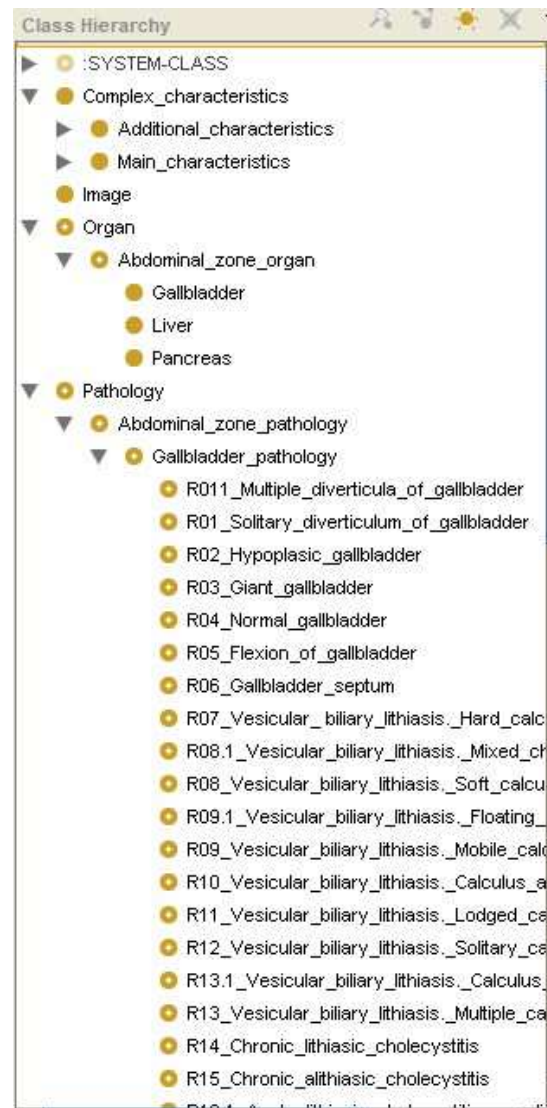

Fig. 2. Class hierarchy for the OUI of hepato-pancreato-biliary zone organs.

As the second source the International Statistical Classification of Diseases and Related Health Problems ICD-10 [2], developed by the World Health Organization, was used.

This classification consists of 22 chapters. In our case, the chapter XI attracts our interest - Diseases of the digestive system, as it includes section K80-K87: Diseases of gallbladder, biliary tract and pancreas.

This section has 5-level structure: I – diseases of the digestive system, II - disorders of gallbladder, biliary tract and pancreas, III - three groups of pathologies (cholelithiasis, cholecystitis and other pathologies which are not included in the first two groups). The other two levels are the consistent differentiation of the third level.

It should be mentioned that there are the variants like “Any condition listed in K80.2 with acute cholecystitis” on the fourth level and “unspecified or without cholecystitis” on the fifth, which allow us to establish a relation when mapping, when there is no one-to-one solution.

A short fragment is shown in Fig. 3 Let's note, that it is only a taxonomy of pathologies, without any information about the anatomy of the organ. From this point of view the integration of two knowledge resources, which allow

getting the full consistent picture, is attractive.

Disorders of gallbladder, biliary tract and pancreas (K80-K87)

K80	Cholelithiasis
K80.0	Calculus of gallbladder with acute cholecystitis Any condition listed in K80.2 with acute cholecystitis
K80.1	Calculus of gallbladder with other cholecystitis Any condition listed in K80.2 with cholecystitis (chronic) Cholecystitis with cholelithiasis NOS
K80.2	Calculus of gallbladder without cholecystitis Cholelithiasis Cholelithiasis Colic (recurrent) of gallbladder Gallstone (impacted) of: • cystic duct • gallbladder unspecified or without cholecystitis
K80.3	Calculus of bile duct with cholangitis Any condition listed in K80.5 with cholangitis
K80.4	Calculus of bile duct with cholecystitis Any condition listed in K80.5 with cholecystitis (with cholangitis)
K80.5	Calculus of bile duct without cholangitis or cholecystitis Cholelithiasis Gallstone (impacted) of: • bile duct NOS • common duct unspecified or without cholangitis or cholecystitis

Fig.3. A fragment of section Diseases of gallbladder, biliary tract and pancreas from the ICD-10.

Thus, the first step of the realization of the task was the creation of mapping between the Diseases Classification ICD-10 and the OUI of the hepato-pancreato-biliary zone organs [3]. As the first step, we deal with the only one organ of abdominal area - gallbladder.

In collaboration with physicians there was created a mapping between semantics of the ICD-10 and the OUI of the hepato-pancreato-biliary zone organs, regarding to the gallbladder (Fig.4).

Let us denote by R_i a list of pathologies from the OUI and K_j a list of pathologies from the classification ICD-10.

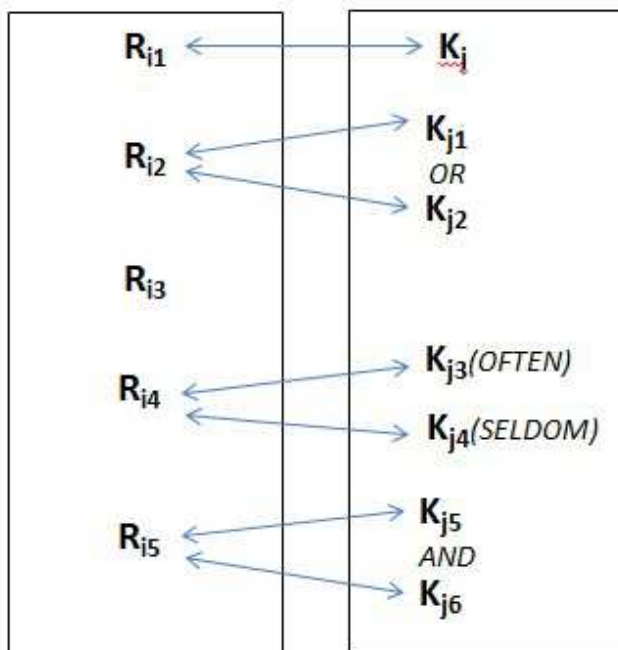


Fig. 4. Relations between semantics of the ICD-10 and

the OUI of the hepato-pancreato-biliary zone organs, regarding to the gallbladder.

In the cases when there is a one-to-one correspondence, there is a mapping from one level of R_i set to the different (2nd and 3rd) levels of K_j .

In the process of establishing of correspondences, according to expectation, we are faced with the following situations:

1) One-to-one correspondence. Example: the pathology R18 Acute lithiasic cholecystitis from our ontology corresponds to the pathology K80.0 Calculus of gallbladder with acute cholecystitis from the ICD-10.

2) The lack of correspondence having in ICD-10 a wider class. Example: The pathology R02 Hypoplastic gallbladder does not match any of the pathologies from the ICD-10, but in ICD-10 there is a section K82.9 (Disease of gallbladder, unspecified), to which the not mentioned in the taxonomy of diseases of gallbladder are related. Therefore, we have established the correspondence with the section K82.9.

3) The absence of the class in the ICD-10, which can be attributed to our rule. Example: R04 Normal gallbladder is not a pathology itself - it is the normal state of the gallbladder, so there is no correspondence.

4) Correspondence with more than one pathology of the ICD-10. For example, the pathology R 26. Acute perforated lithiasic cholecystitis corresponds to two pathologies from the ICD-10 - K82.2 and K80.0

5) Correspondence with one or the other pathology of the ICD-10. For example: The pathology R 43. Diffuse adenomyomatosis of gallbladder in most cases corresponds to the pathology K82.9 from the ICD-10, but rarely it can correspond to K82.8.5

It should be noted that the ICD-10 contains information only about diseases, but not about the anatomical structure of the organ. This information is available in the FMA ontology, for that reason our next step in the continuation of this work will be mapping with the FMA ontology and the development of tools designed for physicians to annotate DICOM images.

ACKNOWLEDGEMENTS

This work was supported by The Academy of Sciences of Moldova – projects: Clinical decision support system in domain of ultrasound examination of the hepato-pancreato-biliary zone (SONARES 13) (13.824.18.170T); Distributed information system "DICOM Network" (14.824.02.186T).

Special thanks to dr. Serghei Puiu - doctor of higher category.

REFERENCES

[1] DICOM, Available: <http://dicom.nema.org/>
 [2] International Statistical Classification of Diseases and Related Health Problems 10th Revision (ICD-10), Available: <http://apps.who.int/classifications/icd10/browse/2010/en/#/K80-K87>

- [3] N. Bruc, G. Magariu, T. Verlan, Elaborating of Ultrasound Images Ontology in Ultrasound Diagnostics, in the International Conference on e-Health and Bioengineering, EHB 2011, Iasi, 2011, In CD, Gr.T.Popa University of Medicine and Pharmacy Publishing House, Iași, România, Editors: Hariton Costin, Alexandru Morega, Liliana Vereștiuc. ISBN: 978-606-544-078-4.
- [4] Manuel Möller, Saikat Mukherjee. Context-driven ontological annotations in DICOM images: towards semantic PACS. HEALTHINF 2009: 294-299.
- [5] The Foundational Model of Anatomy Ontology (FMA), Available: <http://sig.biostr.washington.edu/projects/fm/>
- [6] RadLex Ontology, Available: <http://www.radlex.org/>
- [7] Cojocaru S., Gaidric C. Clinical Decision Support System SONARES// International Journal Information Theories and applications – 2008. - Vol. 15, - N 2. - P. 137-143.
- [8] Burtseva L., Cojocaru S., Gaidric C., Jantuan E., Popcova O., Secrieru I., Sologub D. SONARES - A Decision Support System in Ultrasound Investigations// CSJM, - N 2 (44), - Vol. 15, - 2007, - pp. 153-177.
- [9] Iulian Secrieru, SonaRes methodology enhancement using knowledge discovery technique, Proceedings of the Third Conference of Mathematical Society of Moldova IMCS-50, Chisinau, 2014, ISBN 978-9975-68-244-2, pp. 557 – 562.
- [10] Ontology editor Protégé, Available: <http://protege.stanford.edu/>
- [11] Гайндрик К. В., Кожокару С. К., Брук Н. Л., Магариу Г. А., Верлан Т. Б. Построение онтологии ультразвуковых изображений в области ультразвуковой диагностики, материалы международной научно-технической Интернет-конференции “Информационные системы и технологии”, т. 1, с. 16-22, Орёл, 2011.